Work smarter, not harder:

Automated anterior chamber angle assessment

Introduction

Glaucoma is a group of optic neuropathies primarily classified according to the status of the angle between the iris and the cornea. The iridocorneal angle has long held central importance in glaucoma classification because patients with closed angles behave differently from those with open ones. Broadly, an angle is open when the trabecular meshwork is visible for more than 180 degrees and closed when it is not using gonioscopy (**Figure 1**). While many with angle closure never develop glaucoma, some do, mainly due to elevations in intraocular pressure (IOP). Proper IOP regulation relies on an open access of aqueous humor to the drainage pathway; blockage of this pathway is a common mechanism of IOP elevation and a hallmark of ACG.

ACG is a major health concern, with an estimated 23 million people affected.[1] Certain populations, primarily women, the elderly, and Asians, are at especially high-risk for ACG. Older Chinese women, in particular, have nearly a 25% chance of having angle closure.[2] Angle closure has potentially destructive consequences. In the long-term, angle closure can cause severe, bilateral vision loss through sustained elevation in IOP. Despite accounting for only about one quarter of glaucoma cases, ACG is the cause of half of all glaucoma-related blindness and represents an aggressive form of disease.[3] In China, ACG is responsible for over 90% of glaucoma-related blindness.[4] Angle closure is also the primary risk factor for the development of an acute attack, with potential for devastating vision loss over the course of hours. Furthermore, the recent EAGLE Trial documented the benefit of early lens extraction in ACG making it essential that clinicians assess the angle to select the best treatment approach for patients.[5]

Gonioscopy: a flawed standard

Gonioscopy is currently the standard approach to angle assessment. However, it has several shortcomings that make it a sub-optimal standard and likely contribute to insufficient or improper angle assessment by ophthalmologists.[6] Gonioscopy requires the instillation of numbing drops, a slit lamp, and a trained gonioscopist, usually a physician. Slit lamp gonioscopy also has a steep learning curve, and there is some evidence that ophthalmologist trainees feel inadequately prepared in this technique.[7] Perhaps the main problem with gonioscopy is that it is a subjective measure with only moderate inter-examiner agreement and documented variation with different light conditions.[8,9] Lastly, gonioscopy requires physical contact with the cornea that comes with a host of other concerns: corneal trauma, the need for anesthetic drops, anatomic distortion from lens compression, and patient discomfort.

Despite the significant drawbacks of gonioscopy, it continues to be the most widely used technique for angle assessment. Currently, only half of glaucoma patients have documented angle assessment.[10] Likewise, a recent study found that nearly 1 in 11 patients referred by ophthalmologists to a tertiary care center with the diagnosis of open angle glaucoma had angle closure.[11] Clearly there is need for a better approach to assessing the angle.

Abstract

Primary angle-closure glaucoma (ACG) is a severe disease with a high risk of vision loss and follows a different treatment paradigm from primary open angle glaucoma. Anterior angle assessment is crucial for the diagnosis and management of glaucoma, but gonioscopy, the current reference standard, is not always performed and is subjective. Recent developments in anterior segment imaging and artificial intelligence (AI) offer the possibility of improved angle evaluation. We review recent developments in automated angle assessment and document both the strengths and weaknesses of current AI angle assessment systems. Recent AI performance is impressive, and, while challenges remain, automated angle assessment is largely ready for clinical use.

Matthew C. Johnson, BS
Harvard Medical School, Boston, MA, USA
Department of Ophthalmology, Massachusetts Eye and Ear, Boston, MA, USA

Professor David S. Friedman, MD, PhD, MPH
Harvard Medical School, Boston, MA, USA
Department of Ophthalmology, Massachusetts Eye and Ear, Boston, MA, USA

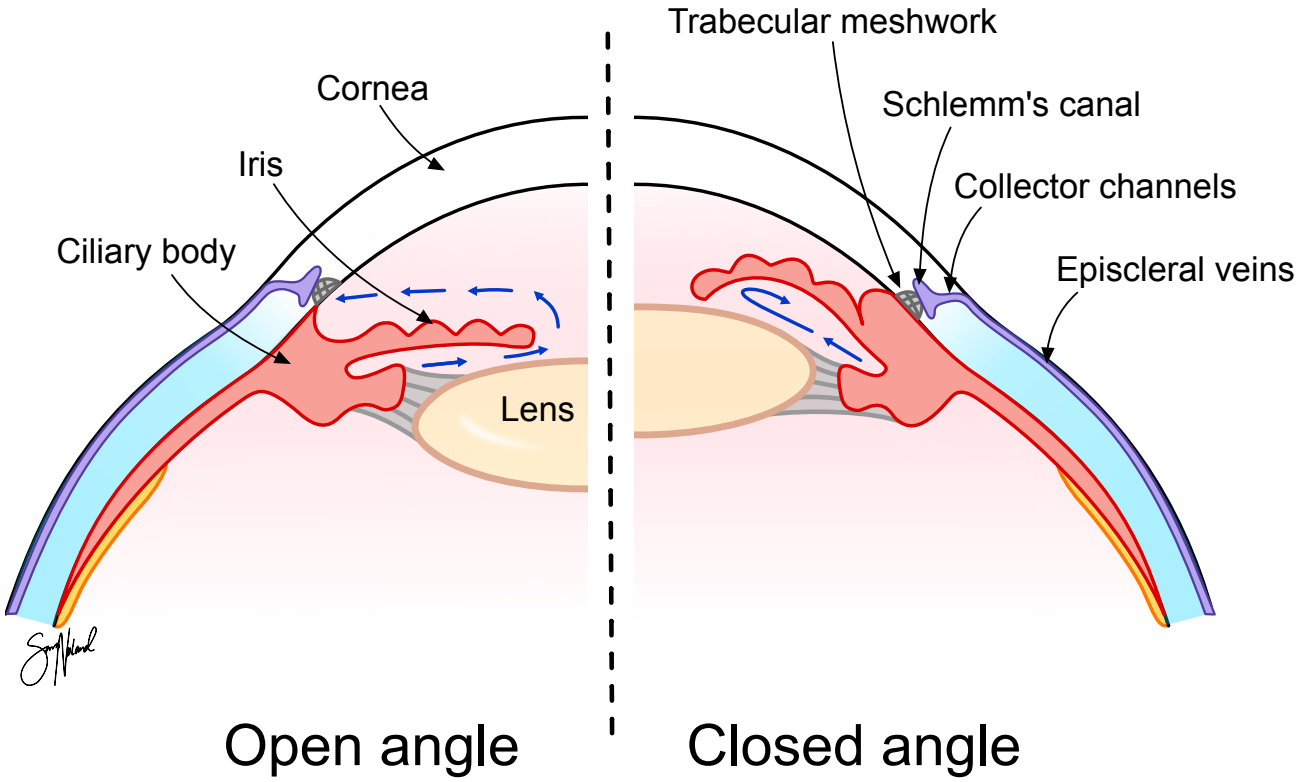

Figure 1. Conventional aqueous humor outflow pathway: *Aqueous humor is secreted by the ciliary body and circulates (blue arrows) from the posterior chamber to the anterior chamber through the pupil. With an open angle (left), aqueous humor exits the eye through the angle where it enters the trabecular meshwork, flows into Schlemm's canal, and merges into collector channels before finally emptying into the episcleral veins. With a closed angle (right), the outflow pathway is impaired.*

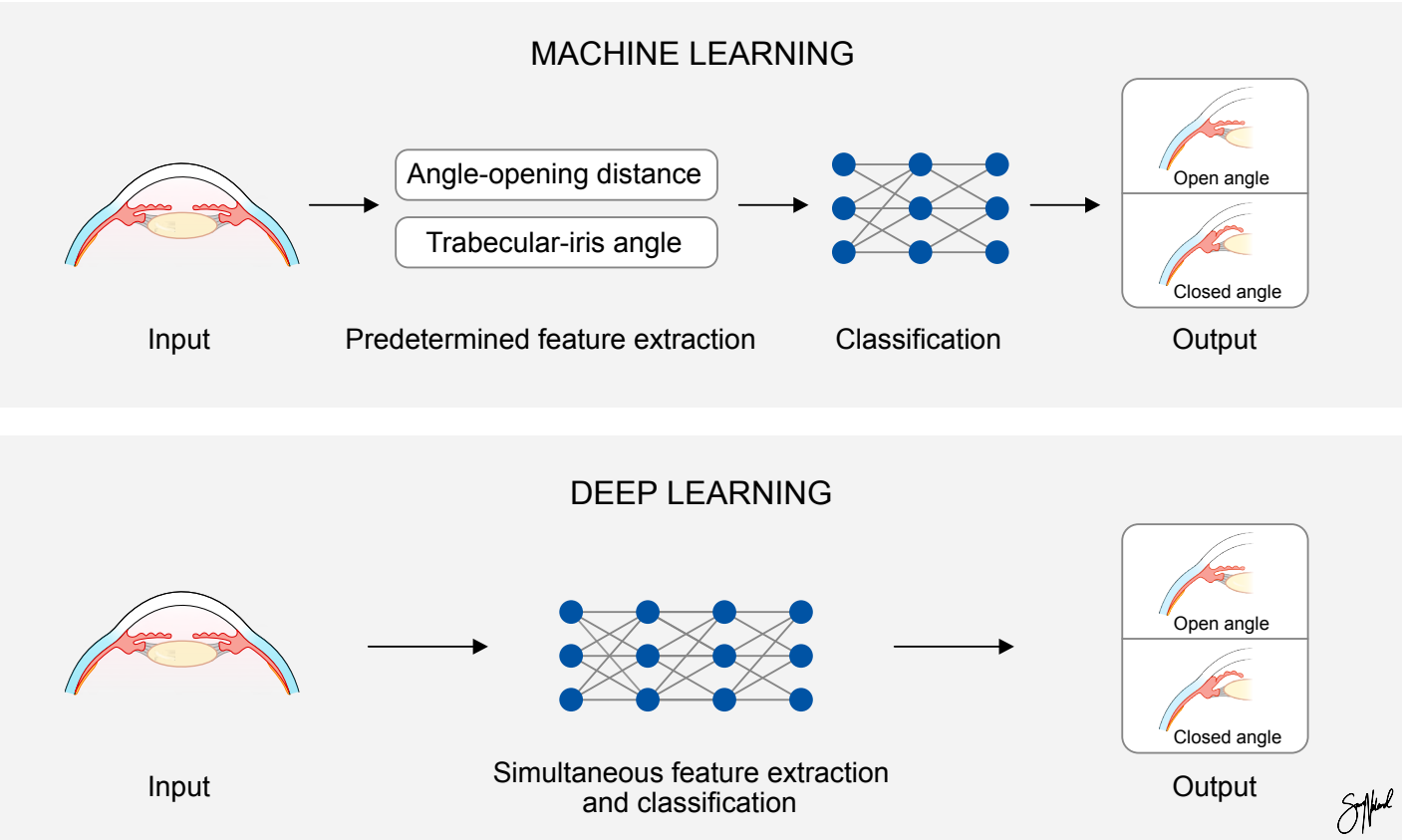

Figure 2. Key distinctions between machine learning and deep learning: Machine learning (top) involves classification based on pre-selected and defined features, whereas deep learning (bottom) enables classification simultaneously with feature selection and testing.

Artificial intelligence in angle-assessment

New, objective, and increasingly automated methods of angle imaging offer the possibility of improved angle evaluation. The two main angle imaging techniques are ultrasound biomicroscopy (UBM) and anterior segment optical coherence tomography (AS-OCT). These methods allow for objective angle assessment, the long-term storage of angle images, and automation.

Anterior segment images can be analyzed and classified by human graders, feature-programmed machine learning, or deep learning. Feature-programmed machine learning involves classifying images using up-front, manual-selected features. Deep learning does not use pre-selected features; instead, a trained algorithm (neural network), learns the most predictive features directly from the images (**Figure 2**). The process of training the neural network requires large datasets in which images have been expertly classified. For each image, the developing network compares its output to the training set value. The neural network then modifies its internal parameters to decrease classification error. With the right training data and after many repetitions, the neural network learns to classify an image accurately and efficiently—without human input.

The use of machine and deep learning in medicine has triggered considerable excitement and has demonstrated early success in the field of ophthalmology. Automated assessment of diabetic retinopathy screening recently gained FDA-approval, and there have been numerous studies using deep learning for age-related macular degeneration and glaucoma screening.[12–15] Using deep learning in the assessment of the anterior chamber angle has also gathered attention and undergone significant pre-clinical testing.

Ultrasound Biomicroscopy

UBM provides high-resolution images of the anterior segment, but its clinical use is limited by practical drawbacks: it is a cumbersome test that requires a skilled examiner, an immersion bath, and physical contact with the eye. UBM's main advantage is its ability to image posterior chamber structures, most importantly the ciliary body and lens zonules. This makes UBM a particularly helpful adjunct tool in diagnosing plateau iris, tumors, and ciliary body cysts.[16] Using UBM, a team of researchers recently described the use of a convolutional neural network (CNN) for angle classification as open, narrow, or closed.[17] They achieved high sensitivity and specificity (all above 96%) compared to physician UBM image grading for each classification using a test set of almost 200 images of each angle type. Likewise, a similar, more recent study demonstrated excellent accuracy and consistency in identifying relevant angle anatomy (**Figure 3**).[18] All intraclass correlational coefficients were above 0.93. Together, these studies demonstrate the promise for automated angle classification of UBM images.

Anterior Segment OCT

AS-OCT is a non-contact and objective imaging modality that can be performed rapidly and reproducibly.[19] While UBM and gonioscopy require a highly-skilled examiner, AS-OCT images can be captured by examiners with less training. AS-OCT clinical applications have expanded over the years as improvements in technology enabled faster image capture and enhanced resolution. Modern swept source systems can now capture circumferential anterior chamber imaging with a resolution of <10 nm x <30 nm at 30,000 A scans per second.[20]

Manual angle assessment requires the localization of landmark structures, particularly the scleral spur. Initially, the limited angle resolution of early AS-OCT devices was a major limitation; the trabecular meshwork could not be reliably identified, and the scleral spur was not visible by expert observers in 15-28% of images.[21,22] Reassuringly, spectral domain

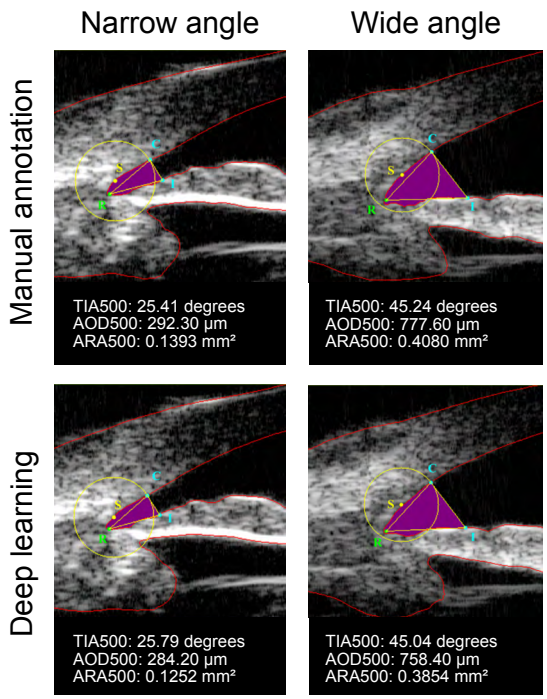

Figure 3. Ultrasound biomicroscopy angle parameter measurement results from manual (top) or deep learning (bottom) algorithms of narrow (left) or wide (right) angles: TIA500 is the angle between points C, R, and I; AOD500 is the distance between points C and I; ARA500 is the area of the purple section. Adapted with permission from Wang et al. Transl. Vis. Sci. 2021.[18]

AS-OCT devices allow for a substantially improved axial resolution and visualization of the scleral spur with high interobserver agreement.[23] Currently, localization of the scleral spur is of primary importance as angle closure in AS-OCT has been defined as any contact of the iris with the angle wall anterior to the scleral spur. Moreover, the scleral spur is used as the reference point to measure other useful angle parameters, including angle opening distance either at 500 or 750 µm anterior to the scleral spur (AOD500, AOD750), angle recess area (ARA), trabecular iris angle (TIA), and trabecular-iris space area (TISA) (**Figure 4**). Overall, AS-OCT has excellent sensitivity (>98%) but poor specificity (~45-65%) in detecting angle closure compared to gonioscopy.[24,25] Pressure- or light- induced angle widening during gonioscopy has been suggested as the cause for this high false positive rate. Therefore, one cannot be certain if gonioscopy is a suitable "gold standard" against which to determine the performance of AS-OCT.

Yanwu Xu et al. demonstrated an early role for AI in AS-OCT angle assessment. They used a computer-aided image processing system (histograms of oriented gradients) to localize the anterior chamber angle and extract several angle features.[26] By combining these extracted features together through the support of vector machine learning, they were able to classify angles as open or closed with higher accuracy (AUC = 0.83) than when using any individual angle feature alone. The next year, the same group presented an improved automated angle assessment system, trained on the same dataset of about 2000 images with an AUC of 0.92.[27]

Fu and colleagues then demonstrated the particular strength of deep learning in angle assessment.[28] They developed a deep learning system for angle classification and compared it to an

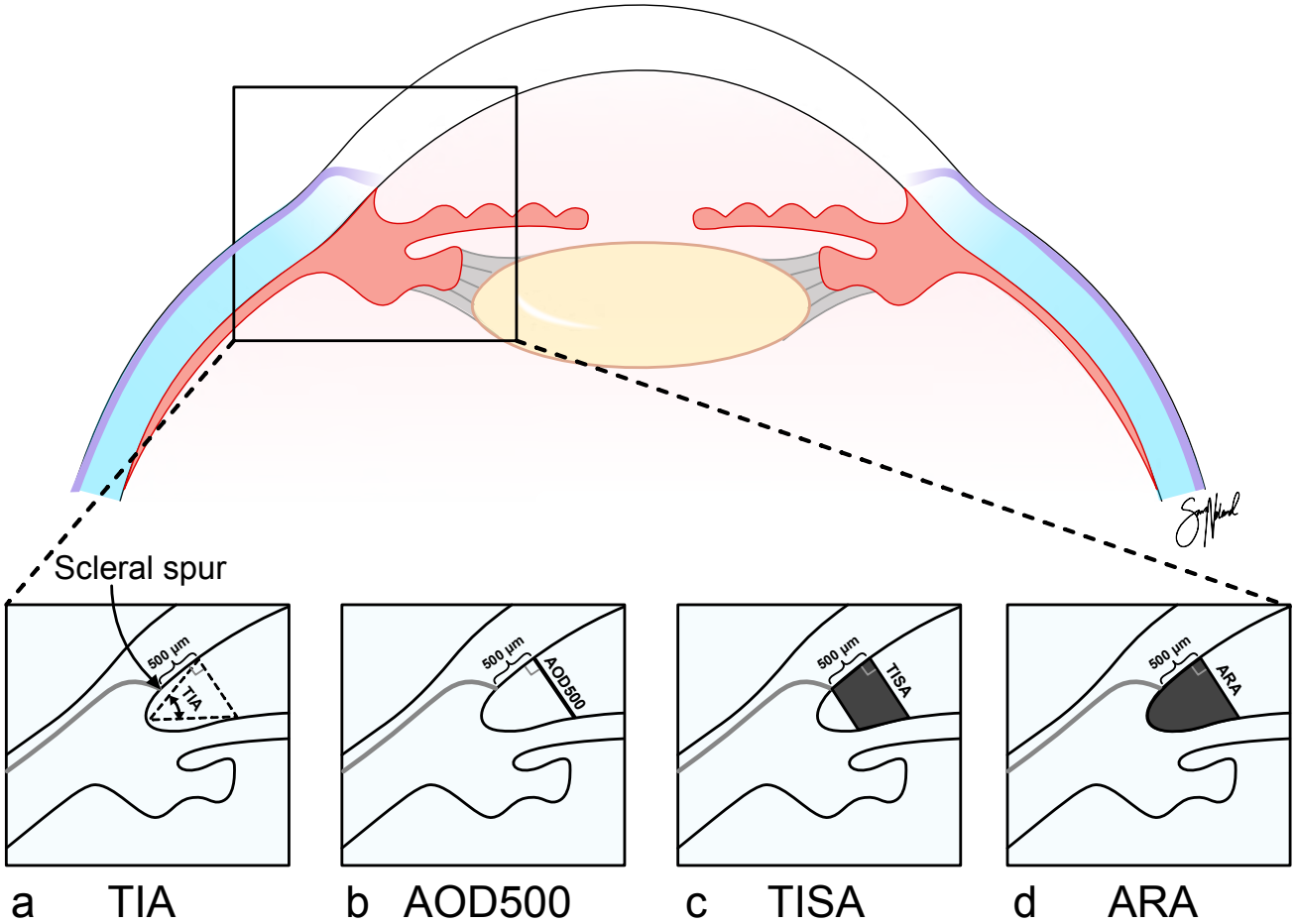

Figure 4. Measurement of various angle parameters: a) the trabecular iris angle (TIA) specifies the anterior chamber angle and is defined as the angle from the apex of the iris recess to the point on the trabecular meshwork 500 µm anterior to the scleral spur and the perpendicular point on the iris. b) the angle-opening distance (AOD500) is the distance from the point on the trabecular meshwork 500 µm anterior to the scleral spur and its perpendicular intersection on the iris. c) the trabecular-iris space area (TISA) is the area bound by the AOD500, iris, inner scleral wall, and line perpendicular to the scleral spur. d) the angle recess area (ARA) at 500 µm is the area of the angle enclosed by the AOD500.

automated, quantitative feature-based system, using physician AS-OCT angle grading as the reference standard (**Figure 5A**). Their quantitative-feature method resembled earlier angle assessment models with automatic segmentation and key feature measurement. Their deep learning model consisted of a VCG-16 network and appropriately identified and focused on the most relevant region to assess angle status (**Figure 5B**). When tested on a set of over 8,270 images (7,375 open angle and 895 closed angle), the deep learning system performed better than the automated quantitative feature-based system when compared to physician grading of the images (AUC 0.96 vs 0.90). This study indicated the ability of neural networks to extract and consider predictive features beyond what physicians currently recognize as relevant.

In 2020, researchers using data from the Chinese American Eye Study developed and tested the ability of a CNN to locate the scleral spur.[29] They trained a ResNet-18 CNN on a dataset of over 17,000 images with the coordinates of the scleral spur marked by one reference grader. In a test set of over 900 images, the CNN performed similarly to a human expert grader with over 80% of predicted coordinates falling within 80 µm of the reference coordinates in both X- and Y-axes, the suggested standard of clinical significance. Moreover, the CNN performed well in variable angle conditions, including eyes with narrow or closed angles, where the scleral spur is more difficult to assess. Work by Pham et al. similarly demonstrated the ability of a CNN to locate the scleral spur as accurately as an experienced ophthalmologist.[30]

Most recently, an international multi-center study using a total of over 1 million images was published. They used a 3-dimensional (3D) deep-learning system and "digital gonioscopy" to assess for angle closure and peripheral anterior synechiae (PAS).[31] This study was unique in several ways. First, it used 3D volume scans to improve image accuracy; second, gonioscopy was used as the reference standard; third, angles were evaluated in both light and dark conditions to simulate dynamic gonioscopy and evaluate for PAS. This deep learning system again demonstrated excellent accuracy, sensitivity, and specificity in detecting angle closure (0.94, 0.87, 0.88 respectively), which was comparable to expert ophthalmologists. More impressively, this "digital gonioscopy" was able to capture PAS using light and dark conditions with 90% sensitivity and specificity (AUC = 0.90) and provide insight into the mechanism of angle closure.

Challenges and Future Directions

Despite the many recent advances, challenges remain that will need to be addressed for AI to change the landscape of angle assessment in clinical practice. First, machine learning algorithms are only as good as the data on which they are trained. Currently, most automated angle-assessment AI systems are trained with datasets of homogenous populations. Thus, few automated systems have been trained or tested against diverse populations more reflective of the real-world.

Second, the absence of ground truth in angle classification poses problems for developing and accessing automated models. What should automatic AS-OCT classification be compared against? Manual AS-OCT classification is somewhat subjective and variable, and gonioscopy, too, is a flawed standard. Additionally, almost all training sets have been assigned "true value classifications" by one or two ophthalmologists. Consequently, automated systems learn any idiosyncratic grading style of their reference trainers, which may threaten external validity. Planning how interpersonal variation should be accounted for will help ensure consistency and widespread applicability.

Third, cost barriers and the variety of AS-OCT imaging modalities are challenges for widespread use of automated angle assessment. General adoption of swept source OCT anterior segment devices have been limited by their high costs, and less expensive alternatives are needed for widespread adoption to be feasible. Current AI algorithms are also limited to a single imaging modality with poor performance when tested on images from a new device. Thus, approval of no single AI system will enable wide-spread accessibility to automated angle assessment, which may slow the pace of development and regulatory approval.

Last, artificial intelligence in angle assessment is still a nascent field with hopefully many more advances and applications to come. One of the more exciting possibilities is the use of AI to predict more accurately who will benefit from prophylactic laser peripheral iridotomy. For AI to realize this potential, continued work is necessary with strategic focus on the transition to clinical models.

Key points:

- Current angle evaluation strategies are subjective and cumbersome.
- Imaging can reduce the burden of assessing the angle.
- Deep learning is an attractive strategy to bring angle assessment into the modern era.
- Deep learning in UBM and OCT have improved tremendously over the years and now demonstrate accuracy and reproducibility comparable to human experts.
- While challenges remain, angle closure screening using automated AI is essentially ready for clinical care.

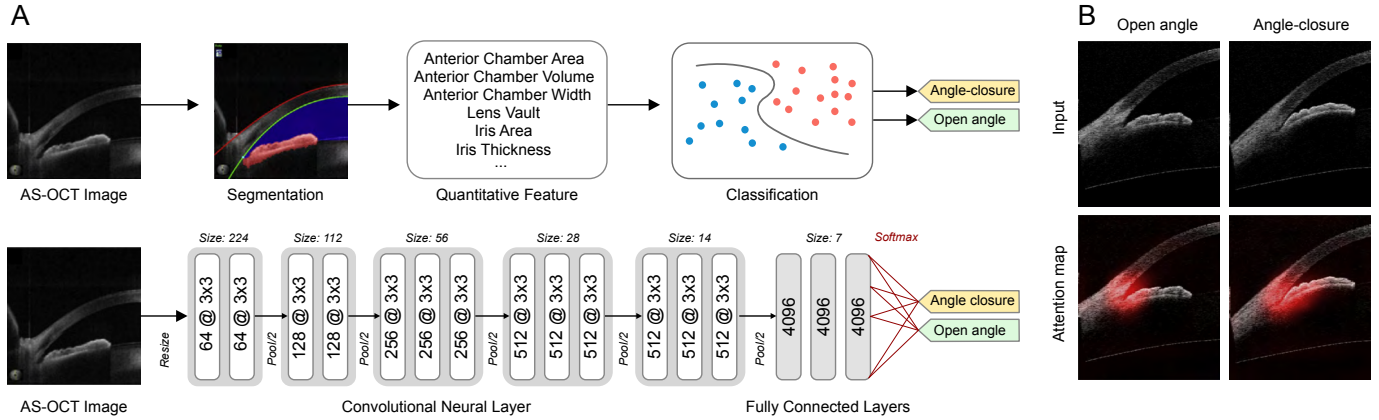

Figure 5A. Overview of automated angle closure detection systems: quantitative feature-based method (top) and deep learning method (bottom). 5B. Attention map of deep learning network highlighting locations of features used in angle classification in open angles (left) and angle-closure (right). Adapted with permission from Fu et al. AJO 2019.[28]

References

1. Tham YC, Li X, Wong TY, Quigley HA, Aung T, Cheng CY. Global Prevalence of Glaucoma and Projections of Glaucoma Burden through 2040: A Systematic Review and Meta-Analysis. *Ophthalmology.* 2014;121(11):2081-2090.
2. Friedman DS, Foster PJ, Aung T, He M. Angle closure and angle-closure glaucoma: what we are doing now and what we will be doing in the future. *Clin. Experiment. Ophthalmol*. 2012;40(4):381-387.
3. Quigley HA, Broman AT. The number of people with glaucoma worldwide in 2010 and 2020. *Br J Ophthalmol*. 2006;90(3):262-267.
4. Foster PJ, Johnson GJ. Glaucoma in China: how big is the problem? *Br J Ophthalmol.* 2001;85(11):1277-1282.
5. Azuara-Blanco A, Burr J, Ramsay C, et al. Effectiveness of early lens extraction for the treatment of primary angle-closure glaucoma (EAGLE): a randomised controlled trial. *Lancet*. 2016;388(10052):1389-1397.
6. Alward WLM. A History of Gonioscopy. *Optom Vis Sci*. 2011;88(1):29-35.
7. Feng R, Luk SMH, Wu CHK, Crawley L, Murdoch I. Perceptions of training in gonioscopy. *Eye*. 2019;33(11):1798-1802.
8. Foster PJ, Baasanhu J, Alsbirk PH, Munkhbayar D, Uranchimeg D, Johnson GJ. Glaucoma in Mongolia: A Population-Based Survey in Hövsgöl Province, Northern Mongolia. *Arch. Ophthalmol*. 1996;114(10):1235-1241.
9. Schirmer KE. Gonioscopy and artefacts. *Br J Ophthalmol* 1967;51(1):50-53.
10. Quigley HA, Friedman DS, Hahn SR. Evaluation of Practice Patterns for the Care of Open-angle Glaucoma Compared with Claims Data: The Glaucoma Adherence and Persistency Study. *Ophthalmology.* 2007;114(9):1599-1606.
11. Varma DK, Simpson SM, Rai AS, Ahmed IIK. Undetected angle closure in patients with a diagnosis of open-angle glaucoma. *Can J Ophthalmol.* 2017;52(4):373-378.
12. Li Z, He Y, Keel S, Meng W, Chang RT, He M. Efficacy of a Deep Learning System for Detecting Glaucomatous Optic Neuropathy Based on Color Fundus Photographs. *Ophthalmology.* 2018;125(8):1199-1206.
13. Grassmann F, Mengelkamp J, Brandl C, et al. A Deep Learning Algorithm for Prediction of Age-Related Eye Disease Study Severity Scale for Age-Related Macular Degeneration from Color Fundus Photography. *Ophthalmology.* 2018;125(9):1410-1420.
14. Burlina PM, Joshi N, Pekala M, Pacheco KD, Freund DE, Bressler NM. Automated Grading of Age-Related Macular Degeneration From Color Fundus Images Using Deep Convolutional Neural Networks. *JAMA Ophthalmol*. 2017;135(11):1170-1176.
15. Abràmoff MD, Lavin PT, Birch M, Shah N, Folk JC. Pivotal trial of an autonomous AI-based diagnostic system for detection of diabetic retinopathy in primary care offices. *npj Digit Med*. 2018;1(1):1-8.
16. Gazzard G, Friedman DS, Devereux JG, Chew P, Seah SKL. A prospective ultrasound biomicroscopy evaluation of changes in anterior segment morphology after laser iridotomy in asian eyes. *Ophthalmology.* 2003;110(3):630-638.
17. Shi G, Jiang Z, Deng G, et al. Automatic Classification of Anterior Chamber Angle Using Ultrasound Biomicroscopy and Deep Learning. *Transl. Vis. Sci. Technol.* 2019;8(4):25.
18. Wang W, Wang L, Wang X, Zhou S, Lin S, Yang J. A Deep Learning System for Automatic Assessment of Anterior Chamber Angle in Ultrasound Biomicroscopy Images. *Transl. Vis. Sci. Technol*. 2021;10(11):21.
19. Li H, Leung CKS, Cheung CYL, et al. Repeatability and reproducibility of anterior chamber angle measurement with anterior segment optical coherence tomography. *Br J Ophthalmol.*. 2007;91(11):1490-1492.
20. Ang M, Baskaran M, Werkmeister RM, et al. Anterior segment optical coherence tomography. *Prog. Retin. Eye Res*. 2018;66:132-156.
21. Sakata LM, Lavanya R, Friedman DS, et al. Assessment of the Scleral Spur in Anterior Segment Optical Coherence Tomography Images. *Arch. Ophthalmol*. 2008;126(2):181-185.
22. Wang BS, Narayanaswamy A, Amerasinghe N, et al. Increased iris thickness and association with primary angle closure glaucoma. *Br J Ophthalmol.* 2011;95(1):46-50.
23. McKee H, Ye C, Yu M, Liu S, Lam DSC, Leung CKS. Anterior Chamber Angle Imaging With Swept-Source Optical Coherence Tomography: Detecting the Scleral Spur, Schwalbe's Line, and Schlemm's Canal. *J Glaucoma.* 2013;22(6):468-472.
24. Nolan WP, See JL, Chew PTK, et al. Detection of Primary Angle Closure Using Anterior Segment Optical Coherence Tomography in Asian Eyes. *Ophthalmology.* 2007;114(1):33-39.
25. Narayanaswamy A, Sakata LM, He MG, et al. Diagnostic Performance of Anterior Chamber Angle Measurements for Detecting Eyes With Narrow Angles: An Anterior Segment OCT Study. *Arch. Ophthalmol.* 2010;128(10):1321-1327.
26. Xu Y, Liu J, Tan NM, et al. Anterior chamber angle classification using multiscale histograms of oriented gradients for glaucoma subtype identification. In: *2012 Conf Proc IEEE Eng Med Biol Soc.*; 2012:3167-3170.
27. Xu Y, Liu J, Cheng J, et al. Automated anterior chamber angle localization and glaucoma type classification in OCT images. In: 2013 *Conf Proc IEEE Eng Med Biol Soc.*; 2013:7380-7383.
28. Fu H, Baskaran M, Xu Y, et al. A Deep Learning System for Automated Angle-Closure Detection in Anterior Segment Optical Coherence Tomography Images. *Am J Ophthalmol*. 2019;203:37-45.
29. Xu BY, Chiang M, Pardeshi AA, Moghimi S, Varma R. Deep Neural Network for Scleral Spur Detection in Anterior Segment OCT Images: The Chinese American Eye Study. *Transl. Vis. Sci. Technol.* 2020;9(2):18.
30. Pham TH, Devalla SK, Ang A, et al. Deep learning algorithms to isolate and quantify the structures of the anterior segment in optical coherence tomography images. *Br J Ophthalmol.*2021;105(9):1231-1237.
31. Li F, Yang Y, Sun X, et al. Digital Gonioscopy Based on Three-dimensional Anterior-Segment OCT: An International Multicenter Study. *Ophthalmology.* 2022;129(1):45-53.

Visit Prague

SOE summer 2023

Average weather for June 15th–17th



Top ten things to do in Prague next summer

1. Attend in-person sessions, debates, symposia, workshops, live surgery, mystery cases at **SOE 2023.** ***See page 45 in the main issue.***
2. Visit the historic **Old Town Square**
3. Take a sunset stroll across the **Charles Bridge**
4. Enjoy a peaceful **cruise on the Vltava river**
5. Visit the **Prague Castle**, the world's largest ancient castle
6. Discover the spectacular **St. Vitus Cathedral**
7. Uncover hidden secrets at the **Museum of Alchemy**
8. Tinker at the **National Technical Museum**
9. Visit the historical **Medical Faculty at the Charles University**, alma mater of famous ophthalmologist Hans Goldmann
10. Have a great time catching up with colleagues at **SOE 2023**