EASDec 2021
ODENSE

Seeing the way forward:

OCT angiography and oximetry as non-invasive diagnostic tools in non-proliferative diabetic retinopathy


Nina C. B.B. Veiby[1]


Aida Simeunovic[2,3,4,5]


Martin Heier[3,5]

Cathrine Brunborg[6]

Naila Saddique[1]


Morten C. Moe[1,4]


Knut Dahl-Jørgensen[3,4,5]


Hanna D. Margeirsdottir[3,5]


Goran Petrovski[1,4]

Abstract

***Purpose**: To determine whether optical coherence tomography angiography (OCTA) and retinal oximetry can detect diabetic retinopathy (DR) before it is visible by ophthalmoscopy.*
***Methods**: Retinal oximetry and OCTA were performed in a cross-sectional study of 166 young individuals with type 1 diabetes (T1D) and 88 healthy controls (mean age: 24.3 years).*
***Results**: Vessel density (VD), measured by OCTA, was significantly lower in T1D patients with no DR compared to controls. This decreased significantly with increasing grade of DR. O_2 saturation inside retinal venules increased significantly with increasing DR.*
***Conclusion**: OCTA and oximetry can detect signs of DR before they are visible by ophthalmoscopy. The decrease in VD can be detected before the increase in O_2 saturation. Increased O_2 saturation in retinal vessels may indicate early microvascular disease and hypoxia.*

Introduction

Diabetic retinopathy (DR) is characterized by microvascular disease, hypoxia, and edema.[1] The oxygen (O_2) saturation in the retinal vessels is affected in DR.[2, 3] This can be measured by non-invasive oximetry, where a fundus camera takes images at two different wavelengths simultaneously.[4,5] The O_2 saturation in larger retinal vessels increases with increasing severity of DR.[2] Early DR is asymptomatic. When visual impairment is detected, chronic or progressive pathology has already developed in the retinal microvasculature. Diabetic macular edema (DME) and proliferative diabetic retinopathy (PDR) are the two advanced stages of DR and the main causes of visual loss in patients with diabetes mellitus. Diabetic macular ischemia (DMI) is due to capillary loss. Before optical coherence tomography angiography (OCTA), DMI required fluorescein angiography (FA) to diagnose. Now, OCTA can detect microvascular changes not visible by ophthalmoscopy at the early stages of DR.[6] OCTA uses the principle of "motion contrast" to detect blood flow and generate high-resolution cross-sectional images of the human retina in a non-invasive and reliable manner. OCTA enables detailed, independent, depth-resolved visualization of the superficial and deep macular capillary plexuses (SCP and DCP), without the need for dye injection. This is particularly useful for studying DMI. OCTA can measure, among others, the vessel density (VD) and foveal avascular zone (FAZ) area, parameters that may have significant functional and prognostic implications in DR.[7] It can play an increasing role in defining the individual prognosis of DR and assessment of treating options.[7–10] In our study, we wanted to confirm whether any detectable

List of abbreviations:
DR—diabetic retinopathy
O_2—oxygen
DME—diabetic macular edema
PDR—proliferative diabetic retinopathy
DMI—diabetic macular ischemia
FA—fluorescein angiography
OCTA—optical coherence tomography angiography
SCP—superficial capillary plexus
DCP—deep capillary plexus
VD—vessel density
FAZ—foveal avascular zone
T1D—type 1 diabetes
NPDR—nonproliferative diabetic retinopathy
NDR—no apparent diabetic retinopathy
TRV—total retinal volume
CMT—central macular thickness

1 Center for Eye Research, Department of Ophthalmology, Oslo University Hospital, Norway
2 Department of Pediatrics and adolescent Medicine, Akershus University Hospital, Lorenskog Norway
3 Department of Pediatric Medicine, Oslo University Hospital, Norway
4 Institute of Clinical Medicine, Faculty of Medicine, University of Oslo, Norway
5 Oslo Diabetes Research Centre, Oslo, Norway
6 Oslo Centre of Biostatistics and Epidemiology, Oslo University Hospital, Norway

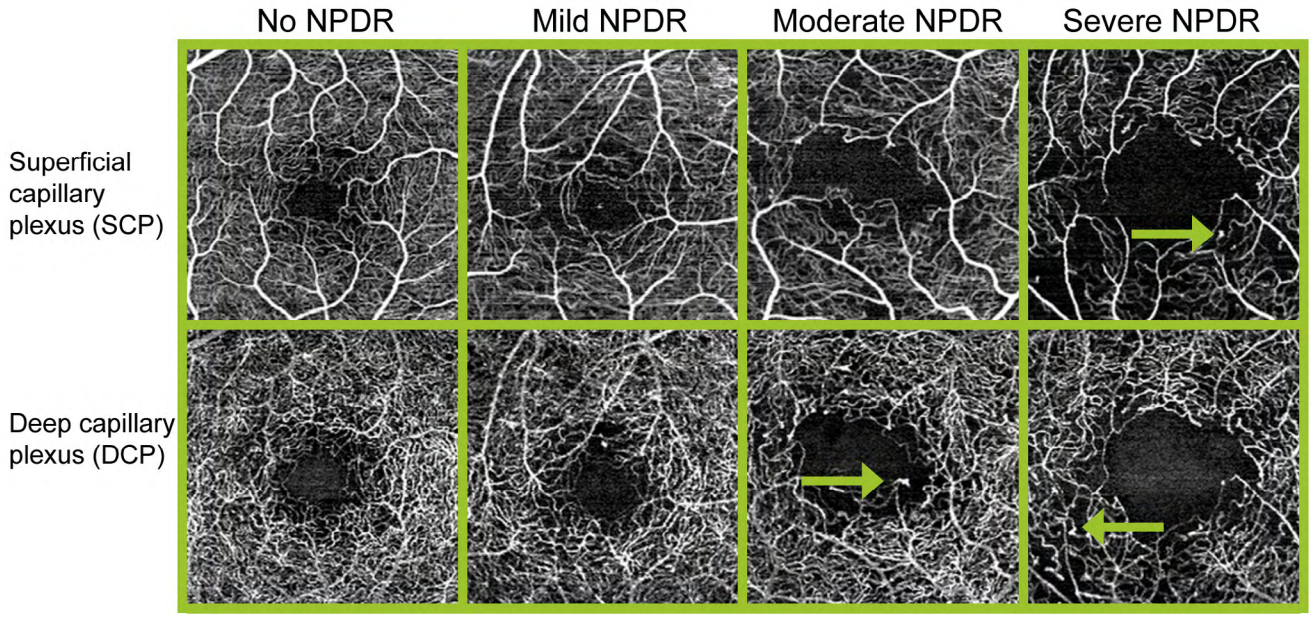

Figure 1. Example OCTA scan of the superficial and deep capillary plexus for different degrees of non-proliferative DR (NPDR) in T1D patients. The FAZ area increases while the vessel density decreases due to capillary dropouts with increasing disease severity. The arrows indicate visible microaneurysms. Adapted with permission from Veiby, N., et al. Associations between Macular OCT Angiography and Nonproliferative Diabetic Retinopathy in Young Patients with Type 1 Diabetes Mellitus. J. Diabetes Res. *2020;2020:8849116*

changes in OCTA and O_2 saturation existed before DR was visible for the clinician, and whether they were associated with the development and progression of DR in young individuals with at least 10 years of type 1 diabetes (T1D).

Methods

We examined both eyes of 166 individuals with T1D and 88 healthy controls from the Norwegian Atherosclerosis and Childhood Diabetes study, an ongoing prospective population-based study of people aged 14–30 (mean age 24.3 years) with childhood-onset T1D (mean duration of T1D 15.7 years). Slit-lamp examination with ophthalmoscopy, OCTA (NIDEK RS-3000 Advance AngioScan, NIDEK CO., LTD., Japan), and fundus photography with oximetry (Oxymap T1, Oxymap ehf., Reykjavik, Iceland) of the macula and optic

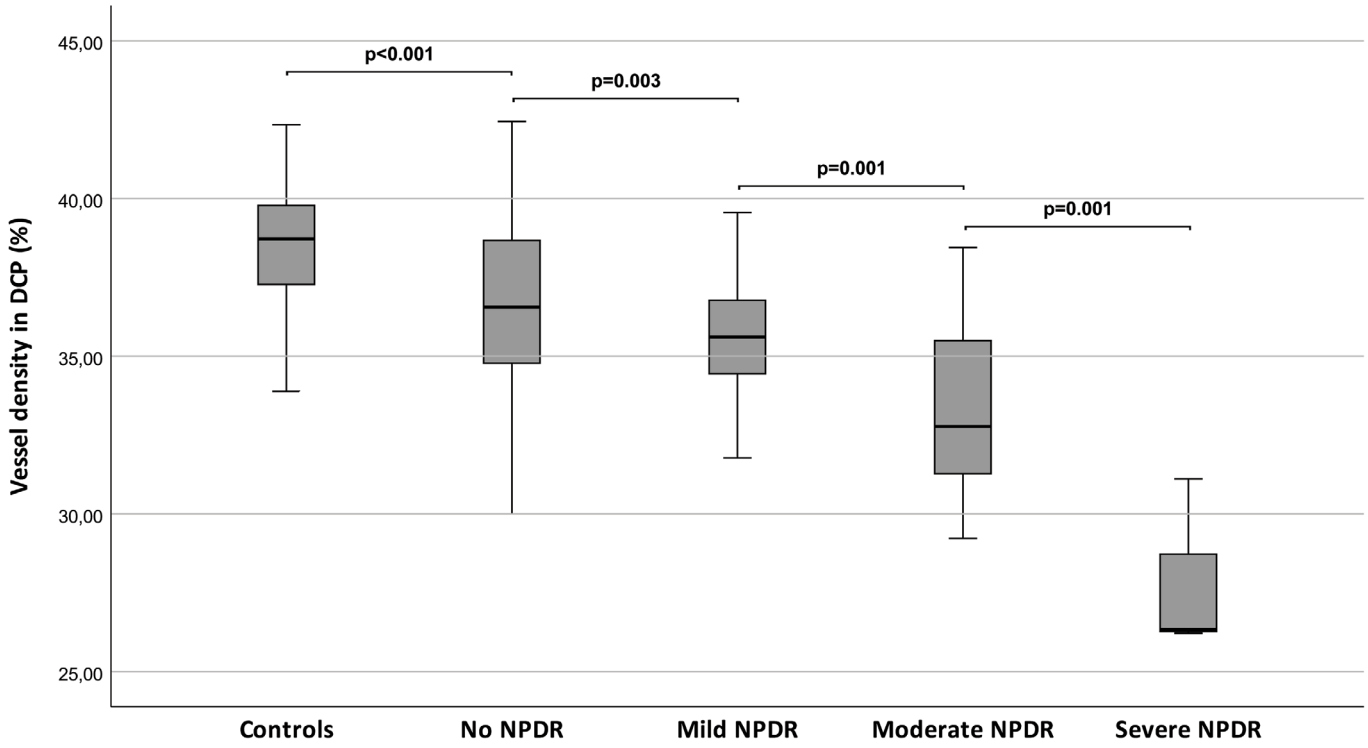

Figure 2. Vessel density significantly decreased with each increasing degree of DR.
Reprinted with permission from Veiby, N. et al. Associations between Macular OCT Angiography and Nonproliferative Diabetic Retinopathy in Young Patients with Type 1 Diabetes Mellitus. J. Diabetes Res. 2020;2020:8849116

disc were performed after pupil dilation. The grade of DR was classified according to the International Clinical Diabetic Retinopathy classification system,[11] and the patients with T1D were allocated into four groups:

0. no apparent diabetic retinopathy (NDR) [n=239 eyes]
1. mild DR [n=58 eyes]
2. moderate DR [n=15 eyes]
3. severe DR [n=3 eyes].

The study only comprised individuals with non-proliferative diabetic retinopathy (NPDR) without DME. Approximately 30% of the T1D patients had DR.

Statistics

Clinical characteristics were presented as means with standard deviations (SD). For oximetry results, only the one eye with most DR from each patient was used. For OCTA results, both eyes were included in the analysis. A generalized estimating equation (GEE) analysis was applied to adjust for intra-individual correlation (since both eyes of each individual were included). An independent sample t-test was used to test for differences in mean OCTA parameters between NDR patients and controls. One-way ANOVA was used to test for differences in mean OCTA parameters between the four NPDR subgroups, and Tukey analysis was used as post hoc pairwise comparison after one-way ANOVA. All statistics were performed using STATA (version 15). A p-value of <0.05 was considered statistically significant.

Results

OCTA findings

VD in DCP was the only OCTA parameter that was significantly associated with the level of DR. VD in DCP was significantly lower in NDR patients than in controls, and it decreased significantly with increasing grade of DR (**Figures 1 and 2**). VD in the SCP, total retinal volume (TRV), and central macular thickness (CMT) were significantly lower in NDR patients compared to controls, but no significant change occurred with the increasing level of DR. No significant differences were found in the FAZ area when comparing NDR patients to controls. The FAZ area was not significantly associated with DR level; it was significantly higher in the severe DR group compared to the other groups (**Figure 1**), but only 3 individuals had severe DR. **Figure 3** shows an example of a small and a large FAZ area in healthy control eyes to illustrate how much the FAZ area can vary.

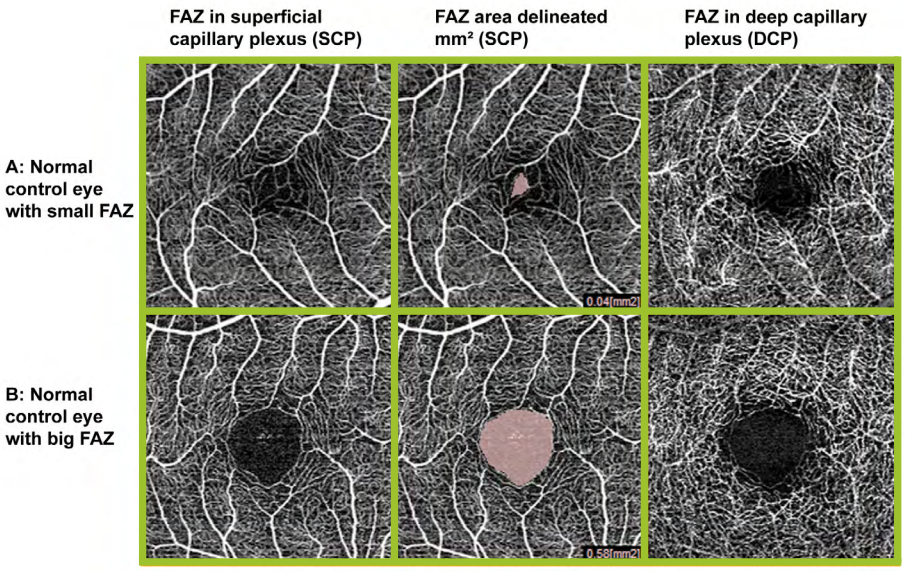

Figure 3. OCTA image showing the foveal avascular zone (FAZ) area delineated, illustrating how much it can vary between healthy eyes. Adapted and reprinted with permission from Veiby, N. et al. Associations between Macular OCT Angiography and Nonproliferative Diabetic Retinopathy in Young Patients with Type 1 Diabetes Mellitus. J. Diabetes Res. 2020;2020:8849116.

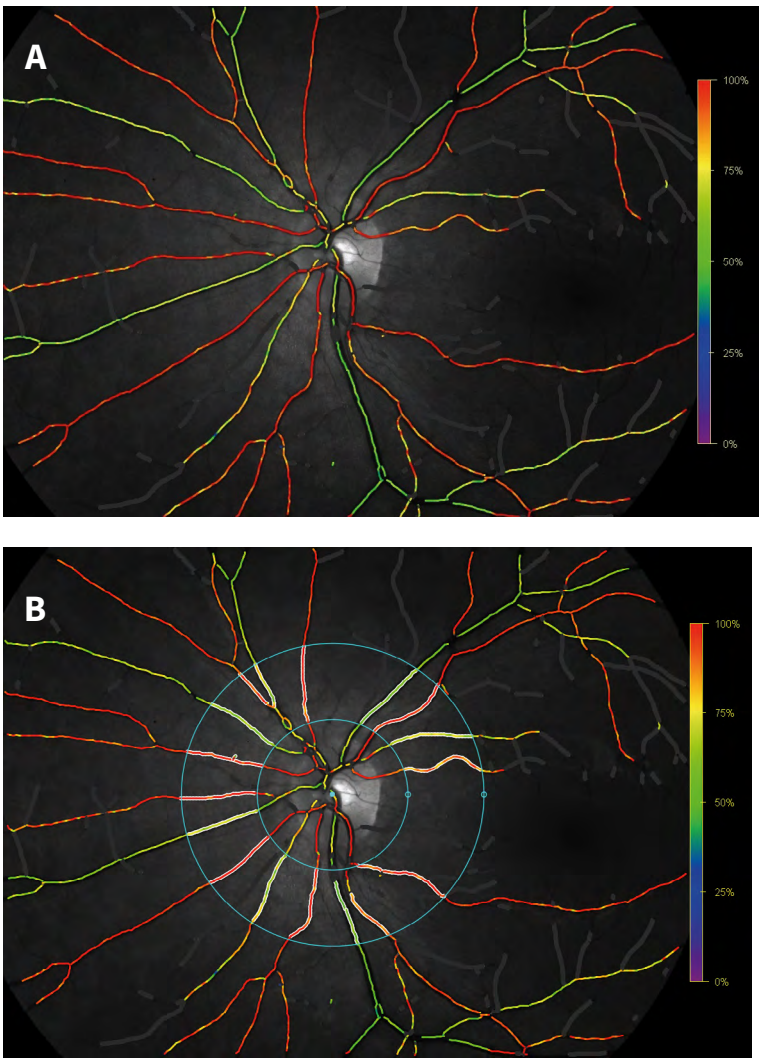

Figure 4. A: Fundus image taken by the oximeter (Oxymap T1). The colors indicate O_2 saturation in retinal vessels according to the scale on the right of the image. The red vessels are arterioles; the green vessels are venules. B: Image of the Oxymap Analyzer (software) showing the measured arterioles and venules within two circles 1.5–3.0 disc diameters from the optic disc center. The white lines indicate the delineations of the vascular segments selected for analysis. Permission to reprint from Veiby, N. et al. Venular oxygen saturation is increased in young patients with type 1 diabetes and mild nonproliferative diabetic retinopathy. Acta Ophthalmol. 2020:98:800-807.

Oximetry findings

The overall arteriolar O_2 saturation levels (mean ± SD) were 90.6% in controls and 91.3% in T1D patients. The venular O_2 saturation levels were 58.2% and 59.3%, respectively. **Figure 4** shows an image of the oximetry analysis. The O_2 saturation in venules increased significantly with increasing grade of DR when adjusting for age; this was not the case for arterioles (**Figure 5**). No significant difference existed in arteriolar and venular O_2 saturation between controls and NDR. The venular O_2 saturation was significantly higher in mild NPDR than in NDR. Arteriolar and venular O_2 saturation were significantly higher in moderate/severe NPDR than in all other groups (**Figure 5**).

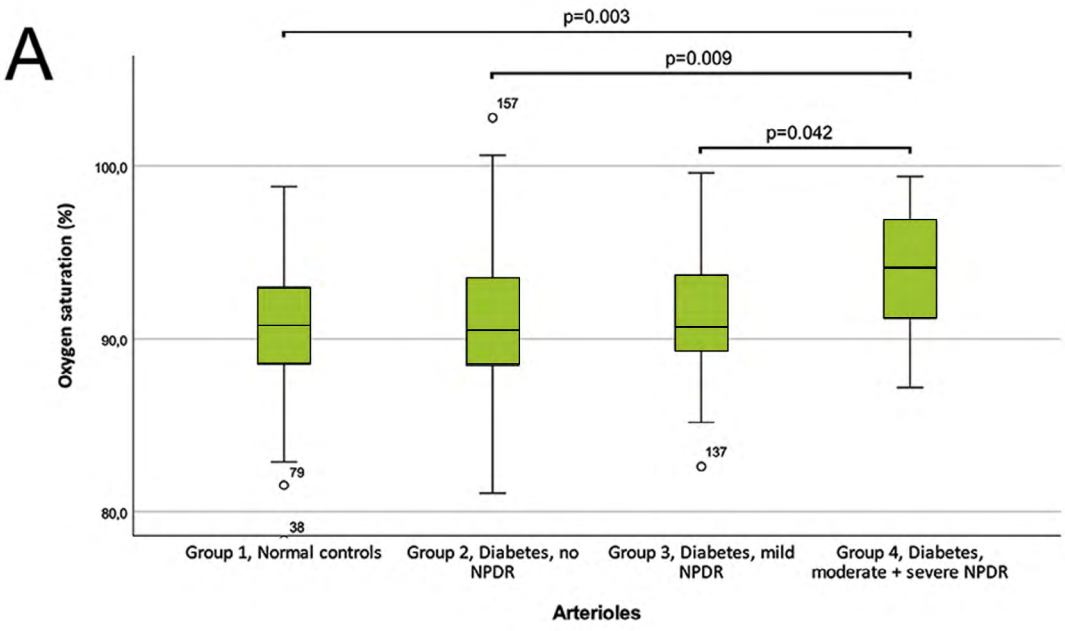

Key points:

- Macular vessel density (VD) on OCTA was significantly lower in patients with T1D without DR compared to controls, and this decreased significantly with increasing grade of DR.
- Venular O_2 saturation increased significantly with increasing DR.
- Arteriolar and venular O_2 saturation were significantly higher in moderate/severe DR than in all other DR stages.
- The decrease in VD can be detected before the increase in O_2 saturation.
- Increased O_2 saturation inside retinal vessels may indicate early microvascular disease and hypoxia.

Discussion

In young individuals with childhood-onset T1D, the VD in DCP was lower in patients with T1D without DR (NDR) than in healthy controls. Lower VD in DCP was significantly associated with increasing severity of DR. Decreasing VD is an early process in DR and is detectable by OCTA before any visible DR by ophthalmoscopy. The O_2 saturation in arterioles and venules increased with increasing level of DR. Specifically, increased O_2 saturation in venules appeared already in mild DR, while in arterioles, the increase appeared in moderate/severe DR. Inside the larger vessels, higher O_2 saturation is a sign of hypoxia in the retinal tissue around the vessels. Although many theories exist as to why this occurs, this is beyond the scope of this paper.[12]

Conventional OCT can also measure TRV and CMT. However, because they were not associated with increasing levels of DR (without DME), OCTA was superior to conventional OCT for detecting changes associated with DR progression. Our data confirm and contribute to previously published data that VD in DCP is the most robust OCTA parameter for the differentiation of clinical stages of NPDR.[13–16] Enlargement of the FAZ area is caused by loss of capillaries in the inner vascular ring around the FAZ. However, this was not significantly associated with DR level, except in severe cases. The FAZ area appears to be an unreliable marker for DR in early stages due to the large variation in size between eyes, even without DR. A recent review concluded that most studies on DR found the FAZ area was larger in patients with diabetes compared to controls, but that this was more evident in patients with advanced levels of DR.[17]

The traditional subjective grading of fundus photos will remain clinically relevant when screening large populations for DR, but it may fail to discover early capillary pathology. Because this is important and only reliably detected by OCTA, OCTA may be included in future screening programs of patients with diabetes mellitus. Evidence suggests that vascular changes, detected by non-invasive OCTA and retinal oximetry, precede the progression to more advanced DR. This may also reflect the status of the microvasculature in other organs, only accessible by invasive biopsies. OCTA has an advantage over FA, which can only show the superficial plexus and cannot be automatically quantified. In addition to being invasive, expensive, and time-consuming, FA has side effects not seen in OCTA.[18–21] Therefore, wide-field OCTA will likely replace FA in the near future.[22]

In conclusion, VD in the DCP measured by OCTA can detect the earliest signs of DR, before they are visible by ophthalmoscopy. Further, it can discriminate between different levels of DR. O_2 saturation in arterioles and venules increases with increasing grade of DR. The decrease in VD can be detected before the increase in O2 saturation, suggesting that this increase is most likely a consequence of microvascular disease (microaneurysms and capillary dropouts). Our results show that increased venular and arteriolar O_2 saturation may indicate early microvascular disease and hypoxia in the retinal tissue, and, thus, can be used as markers for detecting early DR. OCTA and oximetry are reliable tests and may even complement programs aimed at individualizing the control interval for patients with DR in the future.

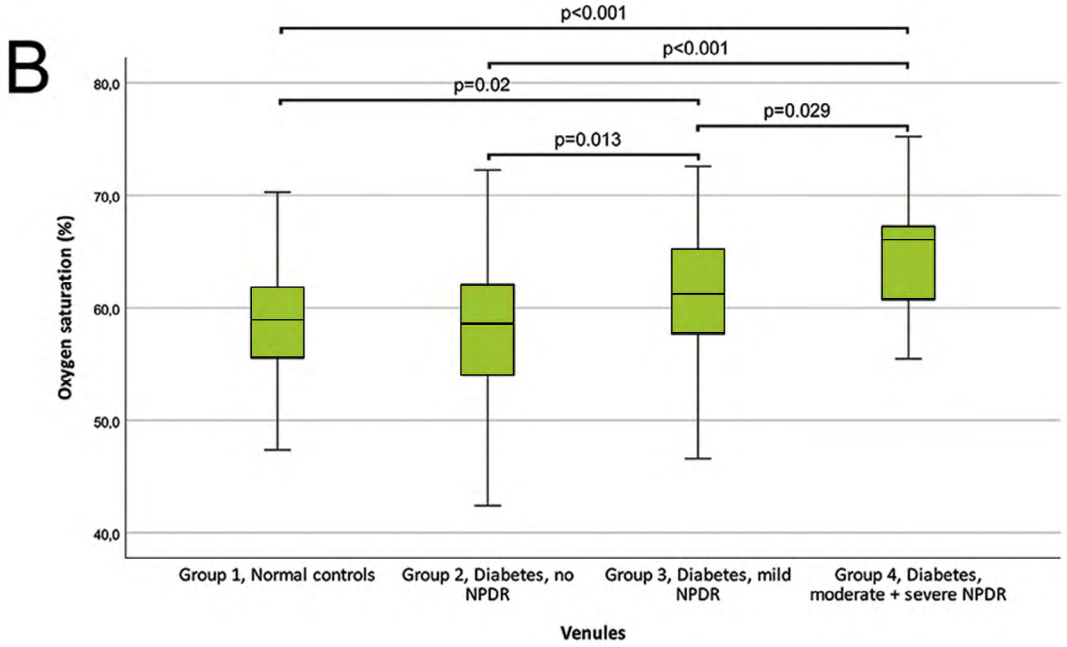

Figure 5. Oxygen saturation in retinal arterioles (A) and venules (B) in the four groups. The boxes show the median and interquartile range. P-values are only shown for the groups that are significantly different. The O_2 saturation in arterioles and venules increased with increasing grade of retinopathy. Adapted and permission to reprint from Veiby, N. et al. Venular oxygen saturation is increased in young patients with type 1 diabetes and mild nonproliferative diabetic retinopathy. Acta Ophthalmol. 2020:98:800-807.

Funding:
The study was supported by the South-Eastern Norway Regional Health Authority [HSO 2017055], the Norwegian Association of the Blind and Partially Sighted, the Dam Foundation [2015/FO4722] and The Norwegian Diabetes Association. The funding organizations had no role in the design or conduct of this research. The Center for Eye Research, Department of Ophthalmology, Oslo University Hospital and University of Oslo receives funding from the Baltic Research Program of the European Economic Area (EEA) grants, project on "Integrated model for personalized diabetic retinopathy screening and monitoring using risk-stratification and automated AI-based fundus image analysis (PerDiRe)" (Contract No. EEZ/BPP/VIAA/2021/8).

Acknowledgments:
Geir Aksel Qvale assisted with images and graphical figures.

Conflicts of Interest:
The authors declare no conflict of interest regarding the publication of this paper. The results have been published in *Acta Ophthalmologica* and *Journal of Diabetes Research*.

This paper is a summary of the following two papers:

1. Veiby N, Simeunovic A, Heier M, Brunborg C, Saddique N, Moe MC, Dahl-Jørgensen K, Margeirsdottir HD, Petrovski G. Associations between Macular OCT Angiography and Nonproliferative Diabetic Retinopathy in Young Patients with Type 1 Diabetes Mellitus. *Journal of diabetes research.* 2020;8849116.

2. Veiby N, Simeunovic A, Heier M, Brunborg C, Saddique N, Moe MC, Dahl-Jørgensen K, Margeirsdottir HD, Petrovski G. Venular oxygen saturation is increased in young patients with type 1 diabetes and mild nonproliferative diabetic retinopathy. *Acta Ophthalmol.* 2020:98:800-807.

References

1. Kohner EM. Diabetic retinopathy. BMJ. 1993;307(6913):1195-9.
2. Hardarson SH, Stefansson E. Retinal oxygen saturation is altered in diabetic retinopathy. Br J Ophthalmol. 2012;96(4):560-3.
3. Hammer M, Vilser W, Riemer T, Mandecka A, Schweitzer D, Kuhn U, et al. Diabetic patients with retinopathy show increased retinal venous oxygen saturation. Graefes Arch Clin Exp Ophthalmol. 2009;247(8):1025-30.
4. Hardarson SH, Harris A, Karlsson RA, Halldorsson GH, Kagemann L, Rechtman E, et al. Automatic retinal oximetry. Invest Ophthalmol Vis Sci. 2006;47(11):5011-6.
5. Hardarson SH. Retinal oximetry. Acta Ophthalmol. 2013;91 Thesis 2:1-47.
6. Gildea D. The diagnostic value of optical coherence tomography angiography in diabetic retinopathy: a systematic review. Int Ophthalmol. 2019;39(10):2413-33.
7. Cheung CMG, Wong TY. Clinical Use of Optical Coherence Tomography Angiography in Diabetic Retinopathy Treatment: Ready for Showtime? JAMA ophthalmology. 2018;136(7):729-30.
8. Early photocoagulation for diabetic retinopathy. ETDRS report number 9. Early Treatment Diabetic Retinopathy Study Research Group. Ophthalmology. 1991;98(5 Suppl):766-85.
9. Photocoagulation treatment of proliferative diabetic retinopathy: the second report of diabetic retinopathy study findings. Ophthalmology. 1978;85(1):82-106.
10. Rodríguez FJ, Staurenghi G, Gale R. The role of OCT-A in retinal disease management. Graefes Arch Clin Exp Ophthalmol. 2018;256(11):2019-26.
11. Wilkinson CP, Ferris FL, 3rd, Klein RE, Lee PP, Agardh CD, Davis M, et al. Proposed international clinical diabetic retinopathy and diabetic macular edema disease severity scales. Ophthalmology. 2003;110(9):1677-82.
12. Veiby NC. Venular oxygen saturation is increased in young patients with type 1 diabetes and mild nonproliferative diabetic retinopathy. Acta Ophthalmol Scand. 2020.
13. Chen Q, Ma Q, Wu C, Tan F, Chen F, Wu Q, et al. Macular Vascular Fractal Dimension in the Deep Capillary Layer as an Early Indicator of Microvascular Loss for Retinopathy in Type 2 Diabetic Patients. Invest Ophthalmol Vis Sci. 2017;58(9):3785-94.
14. Rodrigues TM, Marques JP, Soares M, Simao S, Melo P, Martins A, et al. Macular OCT-angiography parameters to predict the clinical stage of nonproliferative diabetic retinopathy: an exploratory analysis. Eye (Lond). 2019;33(8):1240-7.
15. Bhardwaj S, Tsui E, Zahid S, Young E, Mehta N, Agemy S, et al. VALUE OF FRACTAL ANALYSIS OF OPTICAL COHERENCE TOMOGRAPHY ANGIOGRAPHY IN VARIOUS STAGES OF DIABETIC RETINOPATHY. Retina. 2018;38(9):1816-23.
16. Simonett JM, Scarinci F, Picconi F, Giorno P, De Geronimo D, Di Renzo A, et al. Early microvascular retinal changes in optical coherence tomography angiography in patients with type 1 diabetes mellitus. Acta Ophthalmol. 2017;95(8):e751-e5.
17. Johannesen SK, Viken JN, Vergmann AS, Grauslund J. Optical coherence tomography angiography and microvascular changes in diabetic retinopathy: a systematic review. Acta Ophthalmol. 2019;97(1):7-14.
18. Ishibazawa A, Nagaoka T, Takahashi A, Omae T, Tani T, Sogawa K, et al. Optical Coherence Tomography Angiography in Diabetic Retinopathy: A Prospective Pilot Study. Am J Ophthalmol. 2015;160(1):35-44.e1.
19. Cennamo G, Romano MR, Nicoletti G, Velotti N, de Crecchio G. Optical coherence tomography angiography versus fluorescein angiography in the diagnosis of ischaemic diabetic maculopathy. Acta Ophthalmol. 2017;95(1):e36-e42.
20. de Barros Garcia JMB, Isaac DLC, Avila M. Diabetic retinopathy and OCT angiography: clinical findings and future perspectives. International journal of retina and vitreous. 2017;3:14.
21. Soares M, Neves C, Marques IP, Pires I, Schwartz C, Costa M, et al. Comparison of diabetic retinopathy classification using fluorescein angiography and optical coherence tomography angiography. Br J Ophthalmol. 2017;101(1):62-8.
22. Ishibazawa A, De Pretto LR, Alibhai AY, Moult EM, Arya M, Sorour O, et al. Retinal Nonperfusion Relationship to Arteries or Veins Observed on Widefield Optical Coherence Tomography Angiography in Diabetic Retinopathy. Invest Ophthalmol Vis Sci. 2019;60(13):4310-8.