Navigated retinal photocoagulation for treating proliferative diabetic retinopathy and diabetic macular edema

Findings from two randomized clinical trials

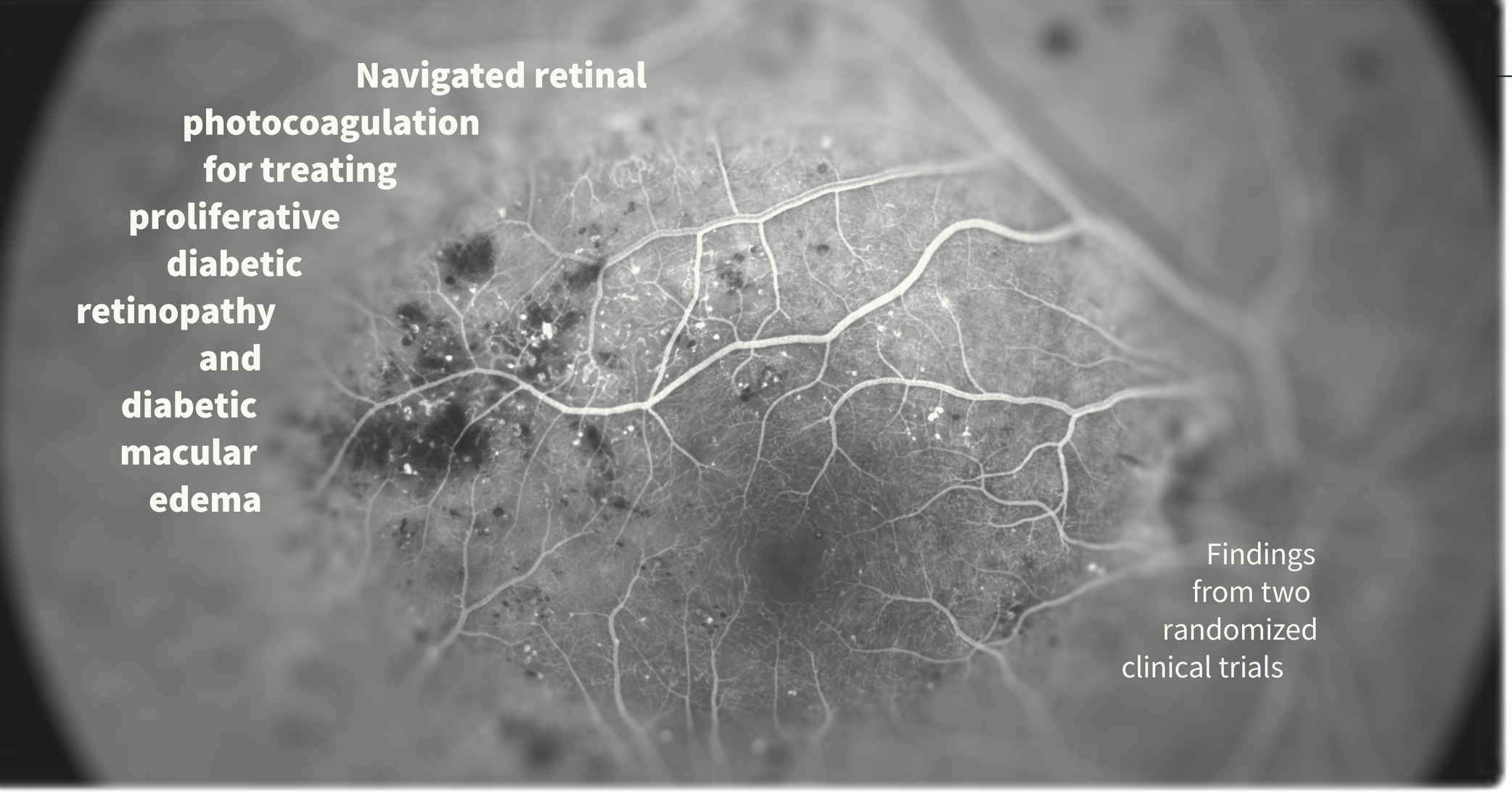

Jakob Grauslund, MD, PhD, DMSci
Clinical Professor, Chief Physician,
Head of Research

Department of Ophthalmology, Odense University Hospital, Denmark
Steno Diabetes Center Odense, Odense University Hospital, Denmark
Department of Clinical Research, University of Southern Denmark, Denmark
Department of Ophthalmology, Vestfold Hospital Trust, Tønsberg, Norway

Diabetic retinopathy (DR) is the most common complication of diabetes and a cause of vision loss.[1,2] As demonstrated by landmark studies such as the Diabetic Retinopathy Study[3] and the Early Treatment Diabetic Retinopathy Study (ETDRS),[4] treatment with retinal photocoagulation for proliferative diabetic retinopathy (PDR) and clinically significant diabetic macular edema (DME) substantially reduces the risk of irreversible vision loss.

In PDR, retinal hypoxia induces vascular endothelial growth factor (VEGF) upregulation, leading to the formation of retinal new vessels. Peripheral retinal treatment with panretinal photocoagulation (PRP) induces photoreceptor atrophy and improves choroidal oxygen diffusion.[5] As PRP lowers the retinal oxygen consumption, the treatment decreases VEGF levels, regressing PDR. Although PRP was a huge advance in the treatment of retinal diseases, concerns remain about its adverse effects, including the increased risk of night blindness and peripheral vision loss.[6]

Although not fully understood, it is believed that VEGF-induced breakdown of the inner blood–retina barrier is a vital component of the pathophysiology of DME. Focal/grid photocoagulation is thought to improve oxygenation, lowering VEGF expression, as in PDR5. Although focal/grid photocoagulation can often halt the progression of DME,[4] intravitreal VEGF inhibition has greater potential for visual acuity improvement.[7] However, direct comparison between focal/grid photocoagulation and intravitreal VEGF inhibition is often difficult.[8] In two recent clinical trials, we tested the efficacy of navigated retinal photocoagulation as a stand-alone or adjunctive treatment in previously untreated patients with PDR and DME.

Navigated photocoagulation in diabetic retinopathy

Navigated photocoagulation using the Navilas® laser system (**Figure 1**) differs substantially from other laser systems. Instead of including a slit-lamp to facilitate preoperative planning, retinal images are displayed on a monitor that uses software to integrate fluorescein angiography or optical coherence tomography thickness maps. Furthermore, an eye-tracking system optimizes the precision of the treatment. The Navilas® at our site uses a 532-nm (green) frequency-doubled, diode-pumped laser. We recently introduced a new 577-nm (yellow) laser as well. Because previous studies had found higher accuracy[9] and less pain and discomfort during treatment,[10] we wanted to evaluate the potential for treatment of PDR and DME through two randomized clinical trials.

Figure 1. Display of the Navilas® laser, which combines eye-tracking with various imaging options and a target-locked frequency-doubled laser.[20]

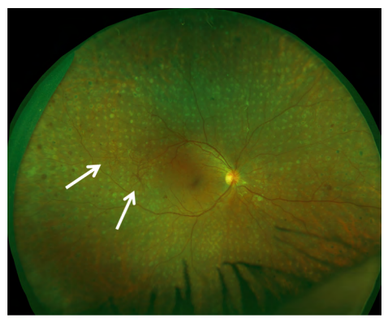

Figure 2. Wide-field retinal image of proliferative diabetic retinopathy with new vessels elsewhere (white arrows) despite full panretinal laser treatment.

Navigated treatment of PDR—lessons from the IMPETUS study

The Individually-Marked PanrEtinal laser phoTocoagUlation for PDR Study (IMPETUS 2018) was a two-fold, clinical PhD study, supported by VELUX FONDEN. The overall aim was to see whether individualized PRP would lead to a better balance between efficacy and adverse effects, compared to the one-size-fits-all PDR treatment, the standard for more than 40 years.[3]

Dr. Thomas Lee Torp performed the first part of the study (IMPETUS-DETECT). Over 6 months, PRP was used in 65 eyes of 52 patients with treatment-naïve PDR to identify potential non-invasive metabolic, structural, and functional markers of postoperative disease activity. Patients received Navilas® treatments over two independent sessions, and postoperative disease progression was identified in 25% and 37% of eyes after 3 and 6 months, respectively (**Figure 2**).

List of abbreviations:

DR—diabetic retinopathy
ETDRS—Early Treatment Diabetic Retinopathy Study
PDR — proliferative diabetic retinopathy
DME—diabetic macular edema
VEGF—vascular endothelial growth factor
PRP—panretinal photocoagulation
IMPETUS—Individually-Marked PanrEtinal laser phoTocoagUlation for PDR Study
DRCRnet—Diabetic Retinopathy Clinical Research Network
ADDENDUM—Aflibercept anD navigateD vErsus coNventional laser in Diabetic macUlar edeMa

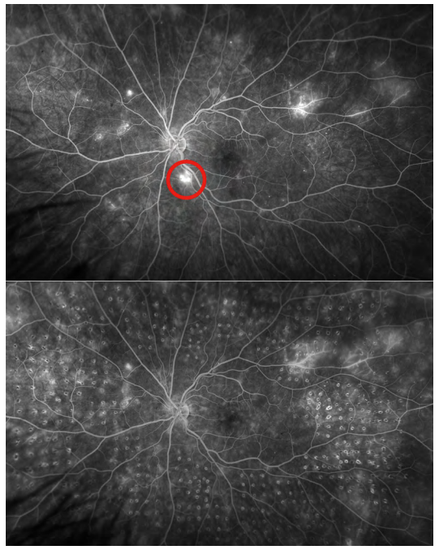

Figure 3. Wide-field fluorescein angiography of patient with proliferative diabetic retinopathy before (upper image) and after (lower image) panretinal photocoagulation. New vessels elsewhere identified by late-stage fluorescein leakage (red circle) before treatment, but in regression after treatment.

We discovered that wide-field fluorescein angiography was often surprisingly difficult to use to assess disease activity after PRP (**Figure 3**). Instead, we found two alternative markers to assess post-operative progression. Retinal oximetry was identified as a potential marker of postoperative disease activity (**Figure 4**). Patients with worse DR have higher retinal venular oxygen saturations[11] because oxygen extraction is impaired in DR. In IMPETUS-DETECT, we demonstrated that each percentage-point increase in retinal venular oxygen saturation from baseline to follow-up was independently associated with a 30% higher risk of associated PDR progression.[12] On the other hand, patients with decreasing retinal venular oxygen saturation were more likely to stabilize clinically after PRP. Peripheral capillary non-perfusion was the second marker identified because patients with subsequent disease progression already had larger areas before navigated PRP.[13]

Based on the finding of IMPETUS-DETECT, Dr. Anna Stage Vergmann tested the effect of individualized navigated PRP in IMPETUS-TREAT. In a 6-month randomized trial, the eyes of patients with treatment-naïve PDR received full navigated PRP (n=27) or individualized navigated PRP (n=26) that only targeted retinal quadrants with active proliferations. The principal endpoints were treatment efficacy and adverse effects, given that full PRP could lead to loss of the peripheral visual field.[6]

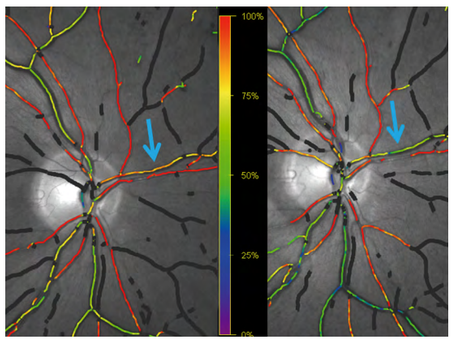

Figure 4. Retinal oximetry as a marker of successful panretinal photocoagulation in proliferative diabetic retinopathy. Decreased retinal venular oxygen saturation was measured as indicated by the color saturation charts with color saturation decrement in specific retinal venular segment (blue arrow).

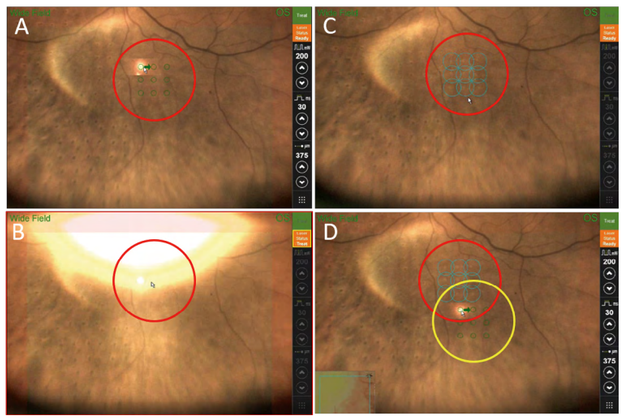

Figure 6. (Above) Navigated panretinal photocoagulation. A: Three by three position pattern planned on the touchscreen (red circle). B: Treatment performed by foot pedal. C: Post-treatment photocoagulation marks can be identified (blue circles in red circle). D: A new position pattern can be identified on the touchscreen (yellow circle).

Figure 5. Navigated panretinal photocoagulation performed by Anna Stage Vergmann, PhD. Image courtesy of VELUX FONDEN.

Key points:

- Navigated retinal lasers have high efficacy and negligible adverse effects in the treatment of sight-threatening complications in diabetic retinopathy.
- Non-invasive retinal markers can be used to predict treatment-outcome in proliferative DR.
- Timely application of focal/grid laser therapy in diabetic macular edema is likely to reduce the treatment burden of intravitreal therapy.

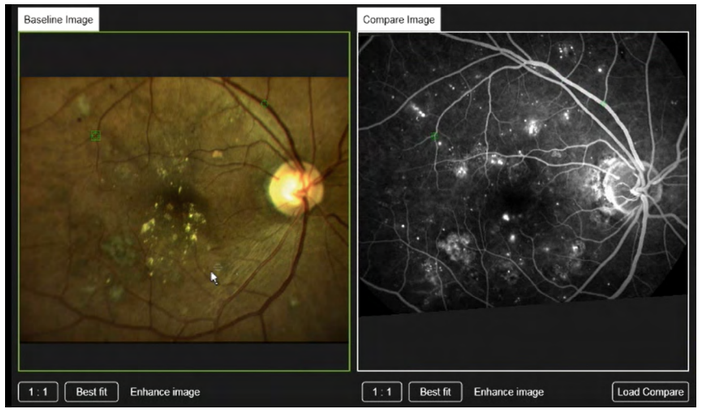

Figure 7. (Left) Navigated focal/grid treatment in diabetic macular edema. Macular image (left side) is captured by Navilas® camera and aligned with previously performed fluorescein angiography (right side) by comparable retinal vascular structures (e.g., branching angles as identified by small green circles and squares).

Hence, we speculated that a more gentle, individualized treatment would lead to fewer adverse effects with the same efficacy.

Six months after treatment, progression of PDR did not differ between patients who received the full or individualized treatment (59.3% vs. 48.0%, p=0.27).[14] Intriguingly, neither group had any measurable adverse effects concerning loss of peripheral vision, dark adaptation, incident DME, or quality of life.[14] The fact that neither full nor individualized navigated PRP induced loss of visual fields was particularly encouraging and in stark contrast to the Protocol S study by the Diabetic Retinopathy Clinical Research Network (DRCRnet), which demonstrated a mean loss of 422 dB for peripheral visual field sensitivity in PDR patients treated with traditional PRP.[15]

ADDENDUM: navigated focal/grid photocoagulation in diabetic macular edema

The Aflibercept anD navigateD vErsus coNventional laser in Diabetic macUlar edeMa (ADDENDUM) study was Søren Leer Blindbæk's PhD research, comparing navigated and traditional focal/grid photocoagulation in addition to intravitreal aflibercept in 48 eyes of 37 patients with treatment-naïve DME. Our earlier review demonstrated that, even in intravitreal angiostatic monotherapy studies of DME, focal/grid laser treatment was often included (e.g., as rescue treatment) in as many as 20–50% of patients, but the exact combination regimen was seldom described in study protocols.[8]

Because we speculated that focal/grid photocoagulation would have the optimal efficacy after aflibercept loading, the ADDENDUM study was designed as a randomized clinical trial with two arms. We compared navigated and conventional focal/grid treatment in center-involved DME-patients, who received loading with three monthly aflibercept injections followed by focal/grid photocoagulation (navigated or traditional PASCAL® laser) and intravitreal aflibercept pro re nata.

In navigated focal/grid treatment, fluorescein angiography is imported and aligned with a real-time macular image (**Figure 7**), allowing treatment to be targeted towards leaking retinal microaneurysms and areas of diffuse leakage, according to ETDRS-protocol (**Figure 8**). The treatment is then performed with assistance from the eye-tracking system and without the need of a contact lens.

At month 12, patients in ADDENDUM

had an average best corrected visual acuity improvement of 8.4 ETDRS letters and a central retinal thickness reduction of 97.4 µm.[16] Even though the principal outcome did not differ statistically significantly between groups, there was a trend toward a better functional outcome in patients treated with navigated photocoagulation (+9.4 vs. +7.1 ETDRS letters, p=0.17).

Most interestingly, after the loading phase, patients in both groups only had a limited need for additional intravitreal therapy after adjunct focal/grid photocoagulation. In fact, during the 12 months of the study, patients received on average only 1.4 intravitreal injections after three loading injections and focal/grid photocoagulation.[16] In other 12-month DME studies such as the DRCRnet Protocol I,[17] RESOLVE,[18] and Da Vinci,[19] similar visual gains were only achieved at the expense of 9.0–10.8 injections within the first year. Therefore, while we did not demonstrate a better effect of navigated laser, the initial results indicate that timely focal/grid photocoagulation after intravitreal aflibercept loading has a beneficial clinical effect and may substantially reduce the need for intravitreal therapy. Long-term studies are important to explore whether these findings can be extended beyond 12 months.

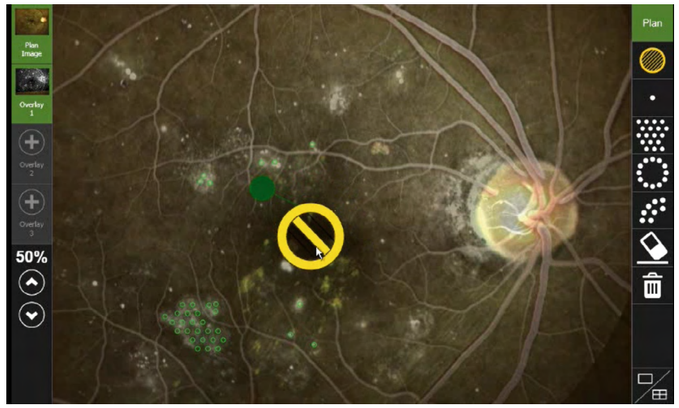

Figure 8. Following Figure 7, an overlap macular image is created, and focal/grid treatment can be planned in accordance with areas of focal and diffuser retinal leakage (green circles). Specific zones that should not be treated (e.g., foveal avascular zone and optic disc) can be identified (yellow circle) before treatment.

Conclusions and perspectives

In IMPETUS and ADDENDUM, we tested the potential of navigated photocoagulation in randomized trials of PDR and DME. In PDR, we demonstrated similar efficacy of individualized navigated PRP compared to full treatment. We were also encouraged by the fact that neither led to any measurable adverse effects.

For DME, the ADDENDUM study indicated that timely focal/grid treatment (regardless of the type) could substantially lower the need for additional intravitreal treatment, if the former was performed after aflibercept loading, which reduced the macular edema sufficiently to optimize the effect of the retinal photocoagulation. We are currently expanding these findings by comparing them with real-life results from our clinical department to implement a better treatment protocol. By combining the visual acuity improvement from intravitreal angiostatic treatment with the lasting effect of focal/grid photocoagulation, we aim to maximize the effect, while lowering the burden of treatment.

The research group:

This article summarizes some of the recent work done by our research group, including studies included in three recent PhD dissertations. I want to recognize and thank the three hardworking PhD students who collaborated with me on these projects.

Thomas Lee Torp, PhD- The Individually-Marked PanrEtinal laser phoTocoagUlation for proliferative diabetic retinopathy Study (IMPETUS-DETECT), 2017

Søren Leer Blindbæk, PhD- Aflibercept anD navigateD vErsus coNventional laser in Diabetic macUlar edeMa (ADDENDUM), 2019

Anna Stage Vergmann, PhD - The Individually-Marked PanrEtinal laser phoTtocoagUlation for proliferative diabetic retinopathy Study (IMPETUS-TREAT), 2020

References

1. Grauslund J, et al. Blindness in a 25-year follow-up of a population-based cohort of Danish type 1 diabetic patients. *Ophthalmology* 2009;116:2170-2174.
2. Grauslund J, et al. Prevalence and 25 year incidence of proliferative retinopathy among Danish type 1 diabetic patients. *Diabetologia* 2009;52:1829-1835.
3. DRS. Preliminary report on effects of photocoagulation therapy. The Diabetic Retinopathy Study Research Group. *Am J Ophthalmol* 1976;81:383-396.
4. ETDRS. Early Treatment Diabetic Retinopathy Study Research Group. Photocoagulation for diabetic macular edema. Early Treatment Diabetic Retinopathy Study report number 1. *Archives of Ophthalmology* 1985;103:1796-1806.
5. Stefansson E. Ocular oxygenation and the treatment of diabetic retinopathy. *Surv Ophthalmol* 2006;51:364-380.
6. Vergmann AS, et al. Changes of visual fields in treatment of proliferative diabetic retinopathy: a systematic review. *Acta ophthalmologica* 2020;98:763-773.
7. Wells JA, et al. Aflibercept, Bevacizumab, or Ranibizumab for Diabetic Macular Edema: Two-Year Results from a Comparative Effectiveness Randomized Clinical Trial. *Ophthalmology* 2016.
8. Blindbaek SL, et al. How do we evaluate the role of focal/grid photocoagulation in the treatment of diabetic macular edema? *Acta ophthalmologica* 2019;97:339-346.
9. Kozak I, et al. Clinical evaluation and treatment accuracy in diabetic macular edema using navigated laser photocoagulator NAVILAS. *Ophthalmology* 2011;118:1119-1124.
10. Chhablani J, et al. Comparison of conventional pattern and novel navigated panretinal photocoagulation in proliferative diabetic retinopathy. *Invest Ophthalmol Vis Sci* 2014;55:3432-3438.
11. Jorgensen CM, et al. The oxygen saturation in retinal vessels from diabetic patients depends on the severity and type of vision-threatening retinopathy. *Acta ophthalmologica* 2014;92:34-39.
12. Torp TL, et al. Changes in retinal venular oxygen saturation predict activity of proliferative diabetic retinopathy 3 months after panretinal photocoagulation. *Br J Ophthalmol* 2017.
13. Torp TL, et al. Peripheral capillary non-perfusion in treatment-naive proliferative diabetic retinopathy associates with postoperative disease activity 6 months after panretinal photocoagulation. *Br J Ophthalmol* 2018.
14. Vergmann AS, et al. Efficacy and Side Effects of Individualized Panretinal Photocoagulation. *Ophthalmol Retina* 2020;4:642-644.
15. Writing Committee for the Diabetic Retinopathy Clinical Research Network. Panretinal Photocoagulation vs Intravitreous Ranibizumab for Proliferative Diabetic Retinopathy: A Randomized Clinical Trial. *JAMA* 2015;314:2137-2146.
16. Blindbaek SL, et al. Aflibercept and navigated versus conventional laser in diabetic macular oedema: a 12-month randomized clinical trial. *Acta ophthalmologica* 2020;98:347-352.
17. Elman MJ, et al. Randomized trial evaluating ranibizumab plus prompt or deferred laser or triamcinolone plus prompt laser for diabetic macular edema. *Ophthalmology* 2010;117:1064-1077.
18. Massin P, et al. Safety and efficacy of ranibizumab in diabetic macular edema (RESOLVE Study): a 12-month, randomized, controlled, double-masked, multicenter phase II study. *Diabetes Care* 2010;33:2399-2405.
19. Do DV, et al. One-year outcomes of the da Vinci Study of VEGF Trap-Eye in eyes with diabetic macular edema. Ophthalmology 2012;119:1658-1665.
20. Chalam KV, et al. Evaluation of a Novel, Non Contact, Automated Focal Laser with Integrated (NAVILAS) Fluorescein Angiography for Diabetic Macular Edema. *Middle East Afr J Ophthalmol* 2012;19:158-162.