Dissertations
FROM THE NORDIC REGION

Ragnhild Wivestad Jansson

Diabetic retinopathy in Western Norway and **early markers of disease progression**

RAGNHILD WIVESTAD JANSSON, CONSULTANT OPHTHALMOLOGIST AT THE DEPARTMENT OF OPHTHALMOLOGY, HAUKELAND UNIVERSITY HOSPITAL, BERGEN, DEFENDED HER DOCTORAL THESIS ON SEPTEMBER 19TH, 2019

Diabetic retinopathy (DR) is the most common diabetes complication. The disease is classified according to the presence and severity of specific microvascular retinal changes. Despite new treatment options and technological advances, the burden of DR is expected to increase. It is important to establish efficient and safe screening protocols for early detection of sight threatening DR and diabetic macular oedema (DMO), since timely treatment can reduce visual impairment and blindness. The purpose of this thesis was to describe the epidemiology of diabetic retinopathy (DR) in type 1 diabetes mellitus (DM1) in Norway and to identify early markers of severe retinopathy.

A randomly selected group of 237 patients with DM1 in Western Norway underwent general and ophthalmologic examinations including fundus photography for grading of DR and DMO, spectral domain optical coherence tomography (OCT) for retinal thickness measurements, and assessment of health-related quality of life (HRQoL). One hundred and fifty-one of these patients underwent additional light adapted full-field electroretinography (ERG) for an objective measurement of general retinal function. More than

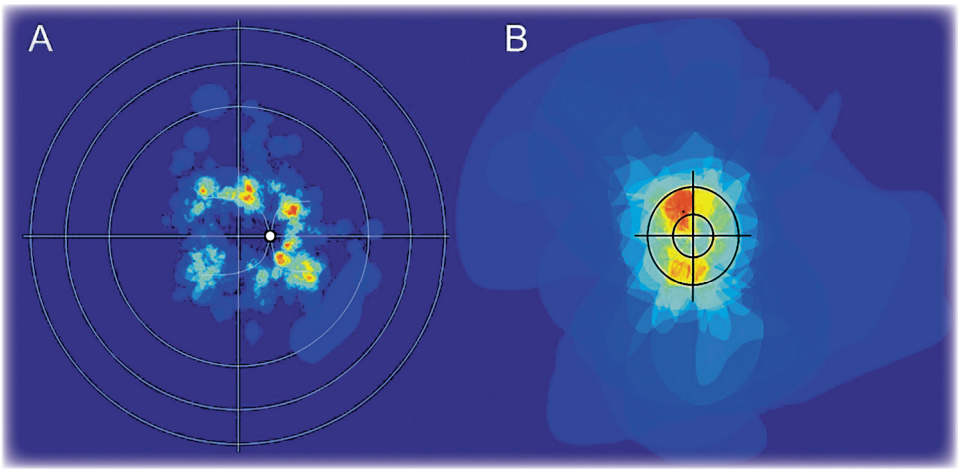

Figure 1: Unfiltered retinal (A) and optic disc (B) chart showing the location and distribution of new vessels elsewhere (NVE) and new vessels on the optic disc (NVD), respectively, in the 174 eyes. The areas with the highest number of overlapping lesions are indicated in dark red.

From left to right: second opponent Professor Jakob Grauslund, Ragnhild Wivestad Jansson, first opponent Professor Einar Stefánsson, chair of the defence Professor Ole-Bjørn Tysnes, chair of the evaluation committee Professor Ingeborg M. Bachmann, and principal supervisor Professor Jørgen Krohn. Photo: Olav Haugen.

half of the DM1 patients (61 %) had DR, showing predominantly mild changes, but 13 % had sight-threatening PDR, and 8 % had DMO. The majority of patients had a best-corrected visual acuity better than driving vision, and none of the study participants were blind. HbA1c and diabetes duration were the strongest predictors of retinopathy severity, yet only 16% of the patients had a current HbA1c below 53 mmol/mol (7%). The patients' HRQoL deteriorated with increasing severity of diabetes, and the general health score among the DM1 patients was significantly lower than in the general population. For all ERG-measurements, the amplitude decreased and the latencies increased with progression of DR, while mean retinal thickness revealed no association with severity of retinopathy.

Fundus photographs of all type 1 and type 2 diabetes patients diagnosed with proliferative diabetic retinopathy (PDR) over a decade, were evaluated. A total of 174 eyes with early PDR were analysed regarding the size and location of new vessels elsewhere (NVE) and new vessels on the optic disc (NVD) (Figure 1). The data were converted into two-dimensional retinal and optic disc charts, merged and displayed as colour-coded contour maps, and analysed in relation to diabetes type, diabetes duration, and recent screening interval. The majority of NVE lesions were located in the nasal fundus hemisphere, essentially inferonasal to the optic disc and along the superior vascular arcades. The NVD showed a predilection for the upper temporal disc rim. Presence of NVD was indicative of more severe disease.

This thesis provides updated information on the prevalence and severity of DR among Norwegian DM1 patients, which may have implications for diabetes management and future screening programs, and may aid early detection and timely treatment of PDR.

Take home messages of the thesis:

1) The prevalence of DR among DM1 patients is largely within the range of previous reports, but the retinopathy is generally milder and develops after longer disease duration. Diabetes duration and HbA1C are the strongest predictors of retinopathy severity. It is important to address metabolic control at ophthalmologic visits.

2) Photopic 30 Hz flicker ERG latencies correspond with severity of retinopathy and may be a future tool for assessment of DR severity. OCT is important for the evaluation of DMO, but mean retinal thickness does not reflect DR severity.

3) NVE has a predilection for the nasal half of the fundus (Figure 1). The presence of NVD indicates a more advanced stage of the disease, and NVD is most often located in the upper temporal quadrant of the optic disc rim.

Photo of Ragnhild Wivestad Jansson: Synne Sofi Bårdsdatter Børnes